

Technical Report

Clinical Evaluation of Affirm Combined Apex Pulse[™] for Treatment of Superficial Photoaging and Scars

Robert A. Weiss, MD

Natalie Bene, MD

Maryland Laser Skin & Vein Institute

The visual signs of superficial photoaging are typically confined to the epidermis and upper dermis (Figure 1) resulting in the typical pattern of textural changes, fine lines, wrinkles and pigmentary alterations. The Combined Apex Pulse[™] (CAP) treatment capabilities in the Affirm laser (Cynosure, Inc., Westford, MA) confines its effects to this zone, while maintaining a low risk of side-effects to provide the opportunity for enhanced outcomes.

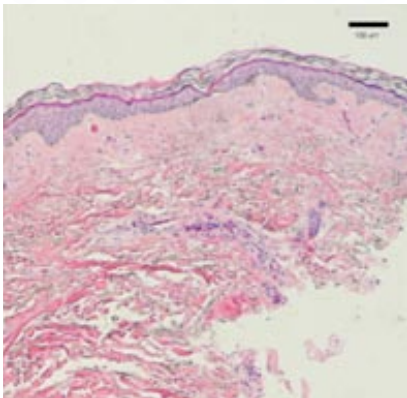


Figure 1.
Typical biopsy of photo-damaged skin showing region of photo-damage (typically 150-250 μ m thick).

Recently, the advent of "micro-rejuvenation" approaches have shown that outcomes for superficial photoaging and like conditions can be improved by creating small, localized zones of significant thermal injury surrounded by untreated skin^{1-3,4}. This approach appears to minimize much of the inflammatory wound healing response, and associated side-effects of other "nonablative" rejuvenation method^{5,6, 5-7}. This approach has also shown promise in the treatment of mature scars.

Abstract presented at ASLMS

Annual Meeting, April 2006

The current micro-rejuvenation approach has several limitations including time consuming set-up and post-treatment procedures, multiple passes to appropriately cover a treatment area (typically 6-8 passes per area), along with subject discomfort necessitating the use of topical anesthesia for most patients.

Infrared wavelengths at low fluences have also been used to improve both tone and texture over the course of 6 or more treatments. While treatments are well tolerated, the results are both subtle and gradual⁸. The mechanism of action of this affect appears to be thermally mediated, as opposed to specific chromophore interaction⁹.

The Combined Apex Pulse array in the 1440-nm Nd:YAG Affirm laser system was developed to combine both mechanisms in a single treatment using high fluence regions surrounded by low level heating. (Figure 2).

This micro-thermal rejuvenation approach creates apexes of high-fluence regions for collagen remodeling surrounded by

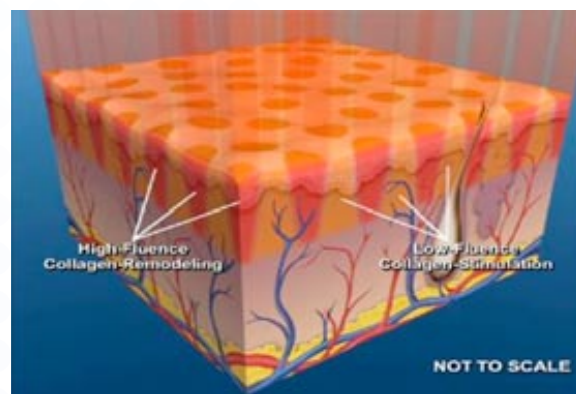


Figure 2.
CAP[™] distribution of heating in tissue. Red shows regions of aggressive heating and collagen remodeling, yellow shows zones of low heating and collagen stimulation.

a collagen-stimulating, low-fluence treatment zone. The CAP array is a special lens construction that consists of approximately 1,000 diffractive elements affecting more surface area per single pulse.

The high-fluence "apexes" create a pattern of coagulated columns, while the background fluence gently heats the intervening uncoagulated tissue. Histologically, the high-fluence CAP columns are limited to approximately 300 µm in depth, constraining treatment to the zone of superficial photodamage¹⁰. This combination of mechanisms is proposed to improve treatment efficacy, while maintaining the side effects profile of existing methods.

The objectives of this study were to evaluate the Affirm laser with the CAP array technology, and determine the safety and efficacy in the treatment of both superficial photodamage and mature scars in addition to determining any limitations of the system.

Methods and Materials

20 subjects were recruited under an IRB controlled protocol, presenting with either superficial photoaging, including facial wrinkles, textural and/or pigmentary changes; or presenting with mature, white scars (including acne scars) on the face or body.

Subjects were evaluated and photographed prior to the initiation of treatment, prior to each subsequent treatment, and one and three months following the final treatment. Subjects received at least three treatments at four-week intervals. As many as six total treatments were permitted for subjects who requested additional treatments. Prior to treatment the skin was cleaned and any makeup was removed.

Subjects were treated using the Affirm laser system at 1440-nm wavelength, 3-msec pulse duration, and 10mm diameter CAP array. Treatment fluences range from 3-7 J/cm², and 1-2 Hz pulse repetition rate. Treatment areas received between

one and three treatment passes, with areas of greater visual defects receiving more passes. All treatments were delivered in conjunction with only SmartCool™ (Cynosure, Inc., Westford, MA) cold-air cooling, with fans speed of between 2 to 4. No additional anesthesia was required. The CAP array requires full contact with the skin for appropriate treatment.

Subjects could resume normal activities immediately following treatment. Biopsies of periauricular test spots were conducted within 3 hours of treatment in those who consented to determine the acute effects of treatment.

Results

90% of patients completed at least 5 treatments, with 78% of the subjects achieving observer graded improvements of at least 26-50% (on a quartile scale). (See figures 3-5)

Treatments were well tolerated with subjects reporting an average discomfort of 2.3 (moderate discomfort) on a 0 (None)-5 (Worst) scale. The CAP technology provides a denser pattern of energy distribution creating a more uniform treatment. This allows treatment with fewer passes and shortens treatment time. Typical initial response to treatment was mild to moderate erythema and edema which resolved within hours to a few days. In rare or one patient case, the treated areas became tan or dusky 36-48 hours after treatment. This transient discoloration resolved within 3 weeks in affected subjects. There were no scars, hyper or hypo-pigmentation observed.

Histology shows that the CAP enabled 1440-nm Nd:YAG laser creates localized regions of injury with limited epidermal damage (no denudation of epidermis). Depth of treatment was limited to the zone of photoaging, and was self-limited to approximately 300 µm depth.

Conclusions

The new 1440-nm Nd:YAG with CAP technology found in the Affirm laser shows exciting new development in nonablative devices for the treatment of wrinkles and scars.

The micro-thermal injury CAP ability shows promise of many different ways to achieve efficacy, though it is still early in developing best parameters.

In addition, clinical applications are expanding to other scar types, wrinkles, and pigmentation. The Affirm laser has proved to be a good compromise between full ablative and previous non-ablative IR resurfacing devices.

Affirm Combined Apex Pulse™

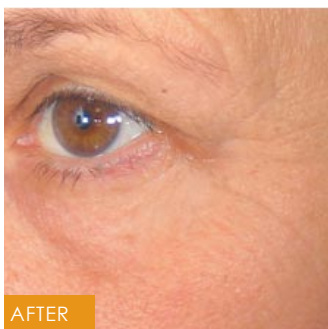
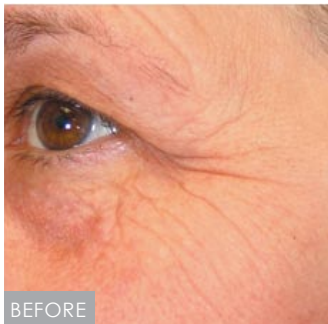

Figure 3.
Tx of peri ocular wrinkles before and 1 month post 3 Tx

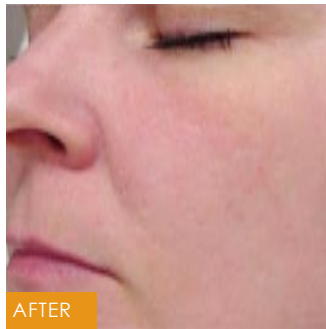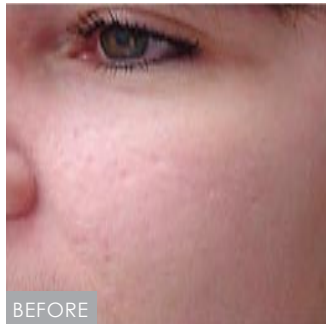


Figure 4.
Tx of acne scars before and 1 month post 1 Tx

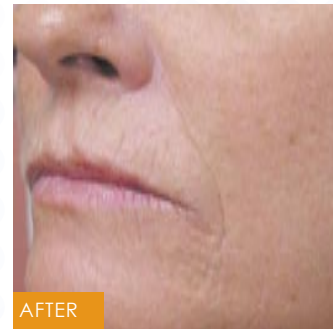
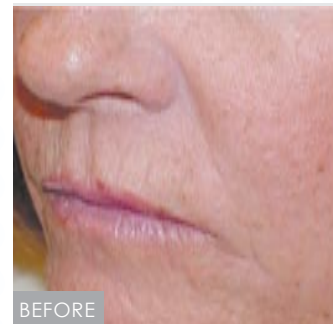

Figure 5.
Tx of peri oral wrinkles before and 1 month post 1 Tx

Bibliography

1. Manstein D, Herron GS, Sink RK, et al.
Fractional photothermolysis: A new concept for cutaneous remodeling using microscopic patterns of thermal injury.
Lasers Surg Med 2004; 34:363-7
2. Rokhsar CK, Fitzpatrick RE.
The treatment of melasma with fractional photothermolysis: A pilot study.
Dermatologic Surgery 2005; 31:1645-1650
3. Bass LS.
Rejuvenation of the aging face using Fraxel laser treatment.
Aesthetic Surgery Journal 2005; 25:307-309
4. Department of Ophthalmology, Division of Plastic and Reconstructive Surgery, Stanford University Medical Center, Stanford, CA. Facial Plastic Surgery Clinic North America. 2001; 9(2):303-10, ix
5. Tanzi EL, Alster TS, Williams CM.
Treatment of facial rhytides with a nonablative, 1450-nm diode laser: A controlled clinical and histologic study.
Dermatologic Surgery 2003; 29(2):124-8
6. Brazil J, Owens P.
Long-term clinical results of IPL photorejuvenation.
Journal of Cosmetics Laser Therapy 2003; 5(3-4):168-74
7. Bjerring P, Clement M, Heickendorff L, Lybecker H, Kiernan M. Dermal collagen production following irradiation by dye laser and broadband light source.
Journal of Cosmetic Laser Therapy 2002; 4(2):39-43
8. Dayan SD, Vartanian AJ, Menaker G, et al.
Non-ablative treatment with the 1064-nm long pulse Nd:YAG laser.
Regional Conference in Dermatology and Facial Cosmetic Surgery, Hong Kong, China, Sept. 15, 2002
9. Dayan SH, et al.
Histological evaluations following 1,064-nm Nd:YAG laser resurfacing.
Lasers in Surgery and Medicine 2003, 33:126-131
10. Weiss RA, et al.
Comparison of histological features of 1550-nm fractional resurfacing and microlens array scattering of 1440-nm. *Lasers in Surgery and Medicine* 2006, Supplement 18